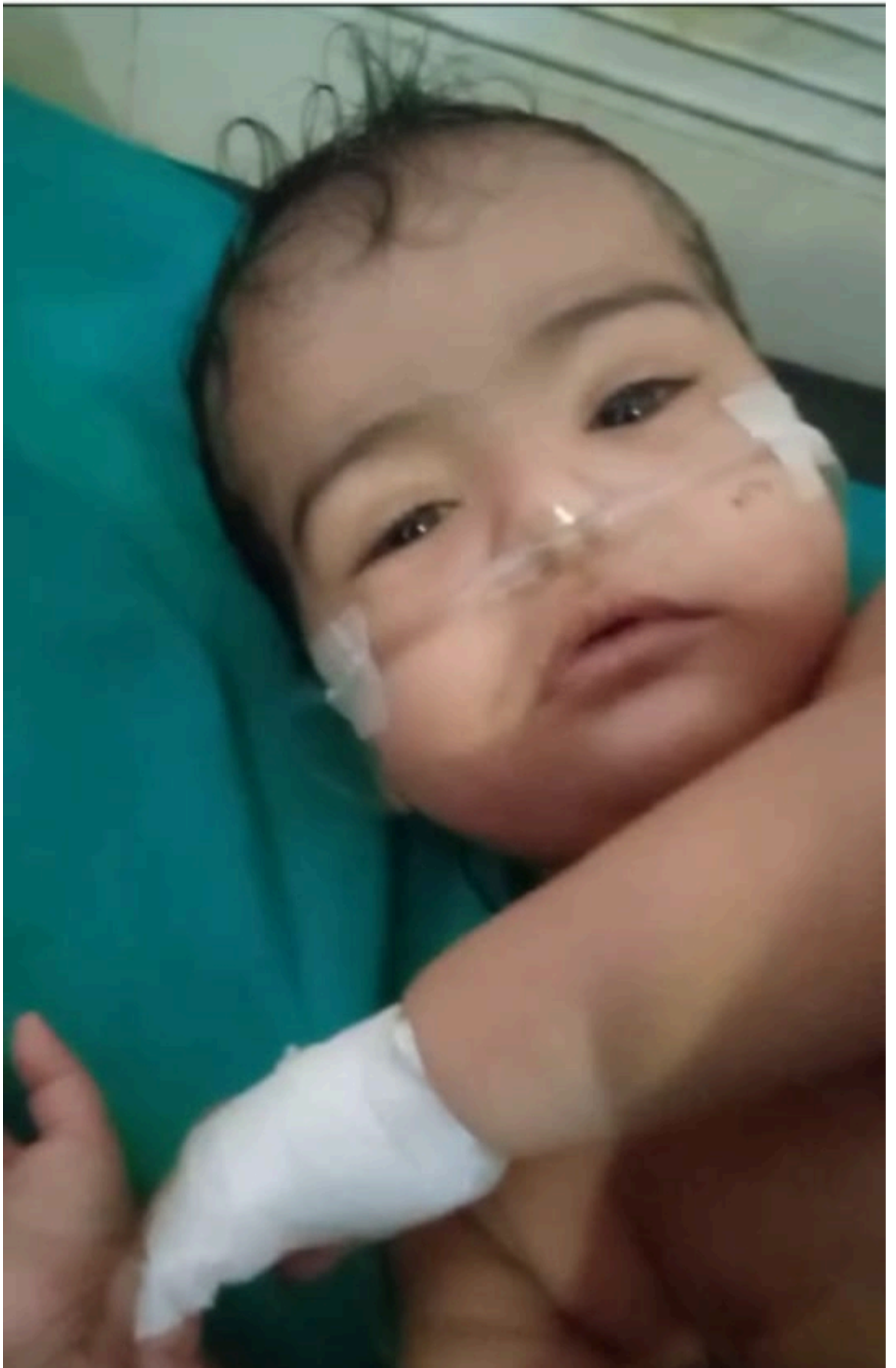
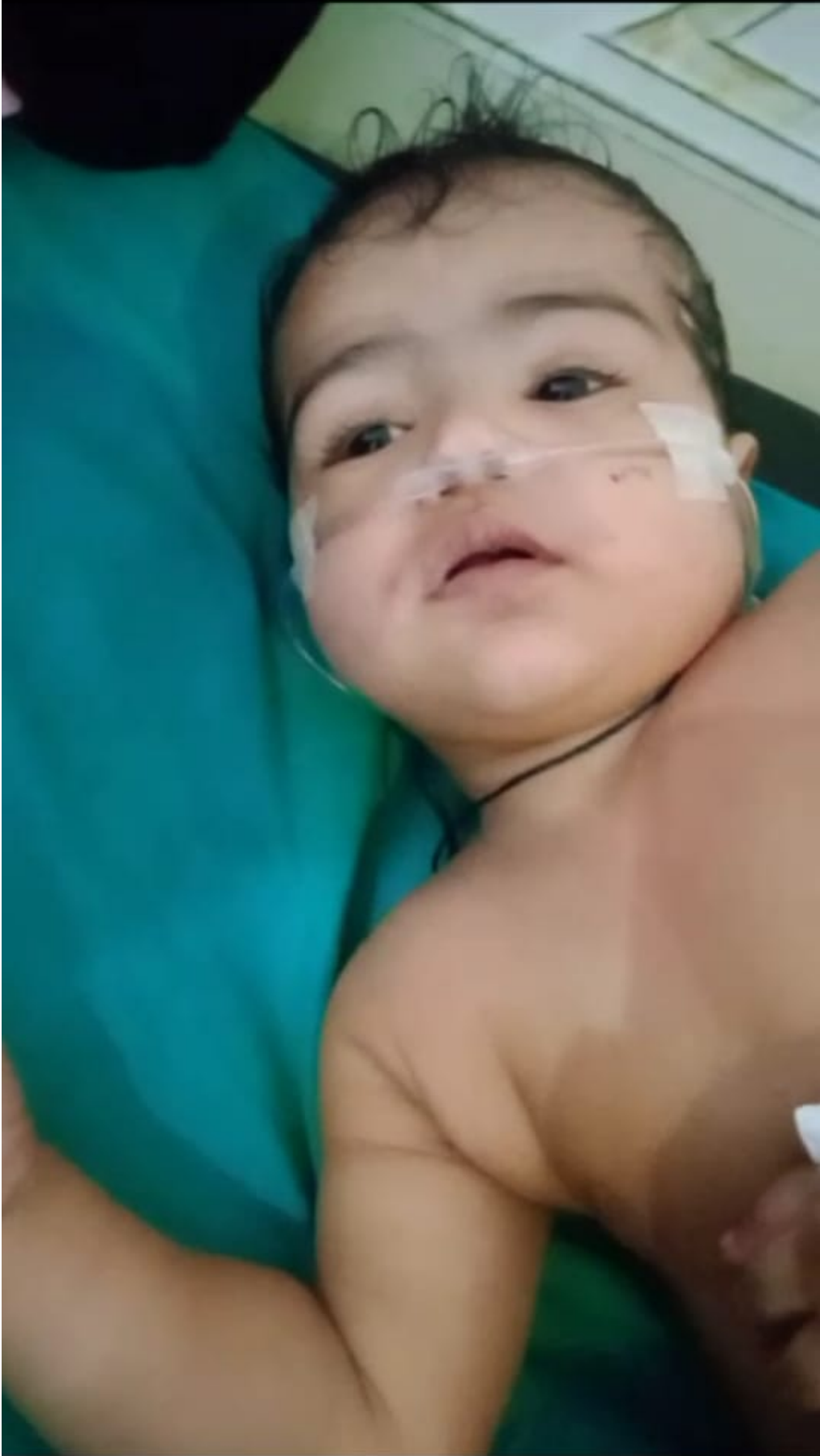
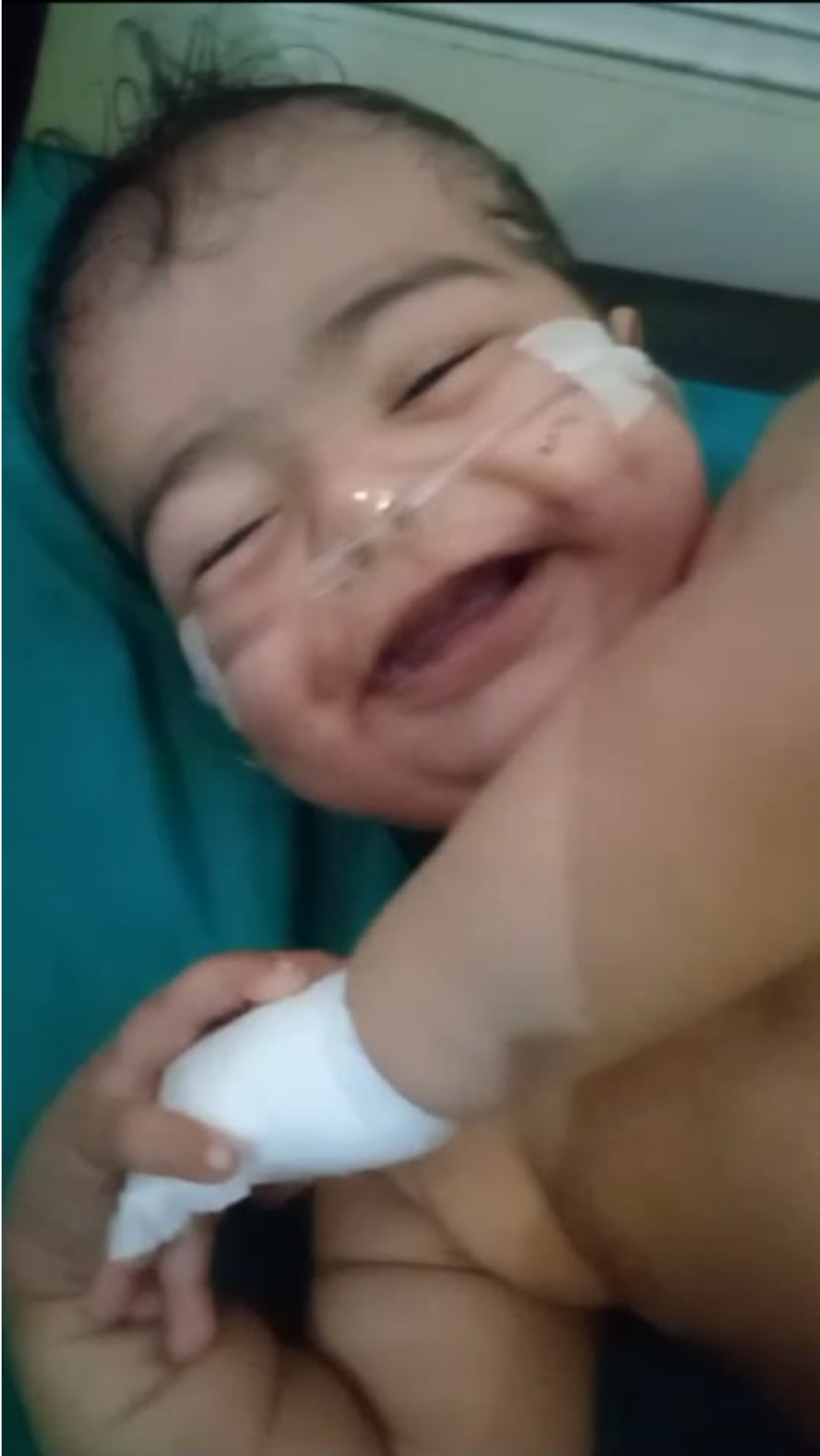





डा. (मैजor) प्रबhat कुमार
Dr. (Major) Prabhat Kumar

MSSS (Siksha) MD (Ped), Dohi University
FMS (Ped Card), MCI recognised
Interventional Pediatric Cardiologist
ECOR in Pediatric, Fellow of CHD in India



Mukunda Child Heart Clinic

हमारे डॉक्टर, (पेडियाट्रिक कार्डियोलॉजिस्ट) बच्चे के दिल में समस्याओं का निदान और उपचार करते हैं।
(पेडियाट्रिक कार्डियोलॉजिस्ट) बच्चे के दिल में समस्याओं का निदान और उपचार करते हैं।

Mobile No.: 7979945262

Email: mukundachildheart@gmail.com

BCMR-41807

Patient's Name: MASTER VEER SINGH

Ref. by Dr.: MAJOR P. K. PANDEY, MD

Date: 10.08.2023

Age/Sex: 9 MONTHS/MALE

ECHOCARDIOGRAPHY REPORT

1. Sinus rhythm, Levocardia
2. AV:VA Concordant
3. SVC & IVC to dilated RA; All pulmonary veins to LA
4. IAS: 5 mm small sized OS ASD, Right to Left flow
5. IVS: INTACT
6. A-V Connection: Ebstein anomaly of TV, Moderate, low pressure TR, gdf= 16 mmHg; Dilated TV annulus; Normal MV with no MR
7. Ventricles: Dilated ARV; Unipartite functional RV; Normal sized LV with normal function (LVEF-56%)
8. V-A Connection: Normal; No AS/AR/PS; Mild PR; Confluent & fair sized branch PAA
9. Aortic arch: Left arch with normal branching pattern; No CoA/PDA
10. Others: No PAH; No PE/Vegetation; Coronaries: Normal

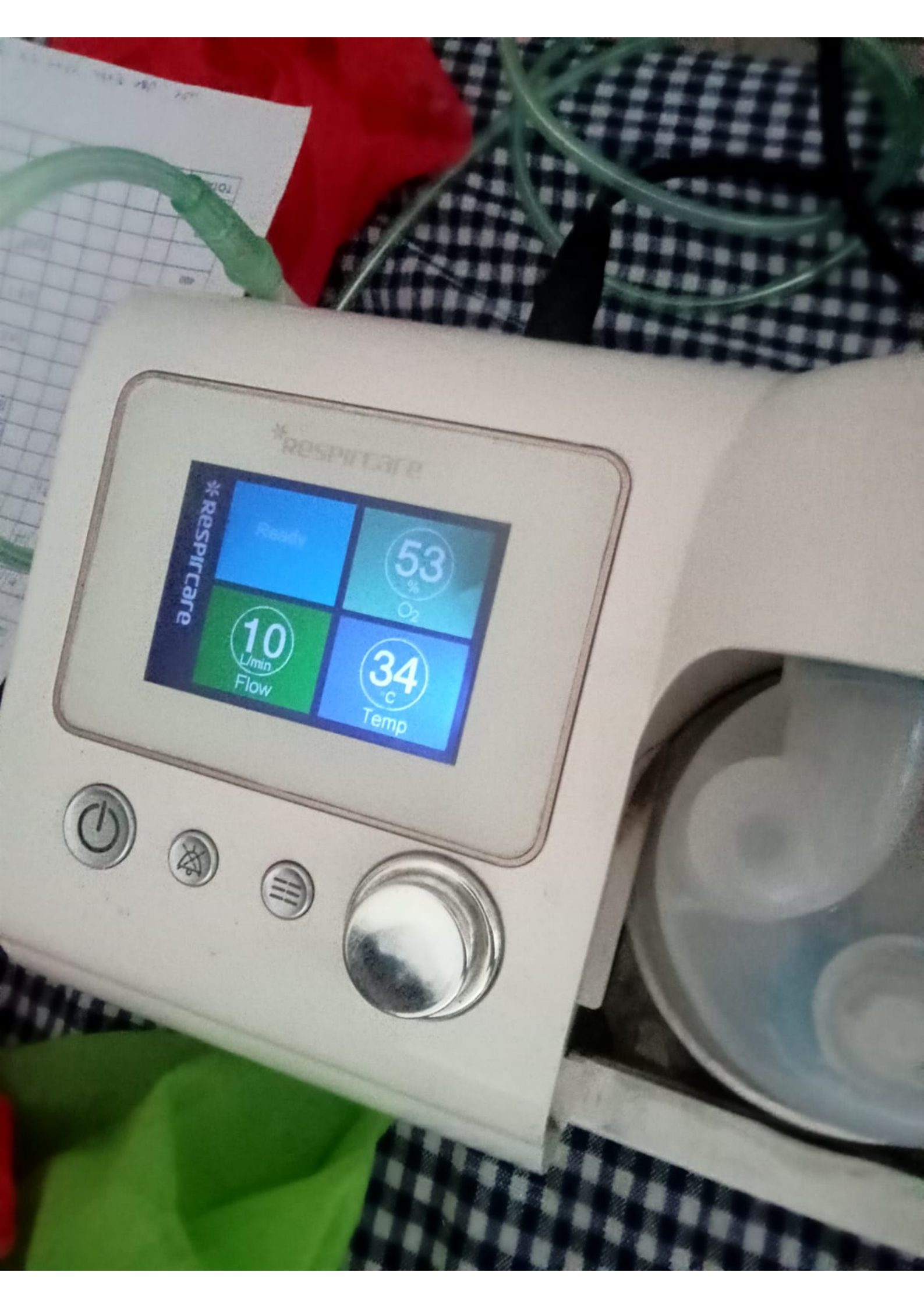
Conclusion:

CYANOTIC CHD
Ebstein anomaly of TV (Moderate, Type B, Grade-3)
Small sized OS ASD
Moderate low-pressure TR
Dilated RA & ARV; Hypoplastic functional RV
Fair LV function

Dr. (Major) Prabhat Kumar
Senior Consultant Pediatric Cardiologist

Thanks for referral

ABU
Surgical correction



*RESPIRCARE

*RESPIRCARE

Ready

53

O₂

10

L/min

Flow

34

°C

Temp



Name -	Mast Veer Singh	Sex /Age -	8 month/M	Date -	23/07/2023
Ref. by -	Maa Mundeshwary Hos	BSA - m ² -		Echo window -	fair

2D Echo – Cardiography & Color Doppler

Mitral Valve Doppler	-	AML – normal morphology	PML – normal morphology
Tricuspid valve Doppler	-	MV Flow – E – 0.9 / A – 0.7	Mitral Regurgitation – no
Pulmonary Valve Doppler	-	Normal	Tricuspid Regurgitation – mod
Aortic Valve Doppler	-	TV Flow – 0.6 m/s	Pulmonary Regurgitation - trace
		Normal	Aortic Regurgitation – no
		PV Flow – 0.7 m/s	
		Trileaflet normal	
		AV Flow – 1.2 m/s	

CONCLUSION -

RA, RV dilated, other cardiac chambers dimension is normal.
Visceral situs solitus, levocardia
Normal AV – VA concordance
SVC and IVC to RA.
All pulmonary vein to LA.
Intact IAS /IVS, No ASD, VSD.
No PDA, no PS.
Left aortic arch, No co-arcation

IMPRESSION -

- ✓ RA, RV dilated, Moderate TR, mild PAH. RVSP = 32 mmHg, Trace PR.
 - ✓ Normal LV systolic function with EF = 65 %
 - ✓ Intact IAS/IVS. No ASD/VSD & No PDA. Lt. aortic arch, no co-arcation.
 - ✓ No clot /vegetation & No pericardial effusion.
- Correlate clinically & with other relevant investigation.

Dr. Amit Srivastava
MS, Mch (CTVS)

(Echo Cardiographer)



Ashirwad

DIAGNOSTIC CENTRE

Address - Adarsh Complex Bypass Road
Near Kali Mandir, Buxar (Bihar)
Email - ashirwadidiagnosticcentre@gmail.com
Mob. No. 9031698138, 9097066836, 9431098848

Patient ID : 22.07.23 05248
Patient Name : VEER SINGH 8M
Test Name : CHEST INCL.ABDOMEN AP VIEW
Referred By : MA MUNDESHWARI HOSPITAL

Test Type : CR
Age/Gender : 000Y/M
Test Done On : 22-07-2023
Reported On : 22-07-2023

X-RAY CHEST AND ABDOMEN AP VIEW

The cardiac size and configuration are within normal limits.
The lung fields are clear. The broncho-vascular markings are normal.
The costo- and cardio-phrenic angles are free.
Both domes of the diaphragm are normal.
No abnormality is seen in the bones and soft tissues of the chest wall.
Distended air containing stomach.
Soft tissue outlines are normal.

IMPRESSION:

- **Distended air containing stomach.**
Suggested clinical correlation



Scan QR for Genuinity Check!

Dr. Vivek C.
Consultant Radiologist
MBBS, DMRD, DNB
Reg. No:- 63426 (KMC)



S.NO.06/23

Date:-20/07/23

Patient Name:- Veer Singh

Age:- 08 Mon Sex:-M

Referred by Dr : - Major P.K.Pandey M.B.B.S. M.D.

TEST	RESULT	NORMAL RANGE
TOTAL W.B.C COUNT	4,900/Cu mm	4000-10000/Cu mm
DIFFERENTIAL W.B.C. COUNT		
NEUTOPHILS	50%	50-70%
LYMPHOCYTES	46%	20-40%
EOSINOPHILS	04%	03-05%
MONOCYTES	00%	01-04%
BASOPHIL	00%	00-01%
HAEMOGLOBIN	7.4gm%	(11.0-14.6gm)
TOTAL R.B.C.COUNT	2.96	3.5-5.5 Million/cumm
HAEMATOCRIT (HCT/PCV)	22.3	37-54mg/d
MCV	59.0	80-100fl
M.C.H.	18.5	27-34p
M.C.H.C.	31.3	31-37pg
PLALETES COUNT	2,43,000	150000-450000cu/mm

Signature

- ❖ Not for medico legal purpose
- ❖ Lab 7:00 AM to 8:PM



शुभकल्प



भारत सरकार
Government of India

भारतीय विशिष्ट पहचान प्राधिकरण
Unique Identification Authority of India

नामांकन क्रमांक / Enrollment No.: 0000/00275/53969

To
चंचल सिंह
Chanchal Singh
W/O: Chandan Kumar Singh,
Ramobariya, Post Majharia,
ward No 14,
VTC: Ramubariya,
PO: Majharia,
Sub District: Barhampur, District: Buxar,
State: Bihar,
PIN Code: 802116,
Mobile: 9525252938

148363454



MG483634543FI



आपका आधार क्रमांक / Your Aadhaar No. :

7471 8625 4806

मेरा आधार, मेरी पहचान



भारत सरकार
Government of India



Issue Date : 26/04/2017



चंचल सिंह
Chanchal Singh
जन्म तिथि / DOB : 20/10/1992
महिला / Female

7471 8625 4806

मेरा आधार, मेरी पहचान

डॉ० (मेजर) प्रभात कुमार
Dr. (Major) Prabhat Kumar
 MBBS (Delhi), MD(Ped), Delhi University
 FNB (Ped Card), MCI recognized
 Intervention Pediatric Cardiologist
 (Expert in Pediatric, Fetal & CHD in Adult)



Mukunda Child Heart Clinic

For all the (48hr on call) Mukunda Nagar, Patna-16
 (Great things are not often seen, but they are always there)
 Mob. No:- 7979945262
 Email:- kumarprabhat79@gmail.com

Major Yash Singh
 9M/8kg
 Date: 16/8/23

Thanks for referral
 Dr. Manoj P. K. Pandey,
 MD



Hb: 7.5g/dl

W/O CHD
 for severe 2opimus
 of incidental murmur
 during LRTD

Echo

CIE: Cyanotic +
 SpO2 = 85-92%,
 HR = 120/min
 CRT: Multiple clicks

Ebstein's Anomaly of TV
 Small ASD, R→L
 Dilated RA/ARV
 Small RV
 (Outlet/Inferiorly)
 Moderate, low pressure
 TR

- Cyanotic CHD
- Ebstein's Anomaly
- Anaemia

No PS/AS
 GUF

Adv
 ① Drop Furosemide 0.4ml x 2
 (80%)

② Tab. Aldactone (25mg)
 4hr x 2

③ Any iron to continue



सत्यमेव जयते
भारत सरकार

सत्यमेव जयते



आधार

भारत सरकार
Government of India

भारतीय विशिष्ट पहचान प्राधिकरण
Unique Identification Authority of India

नामांकन क्रमांक / Enrollment No.: 0000/00380/54911

To
चन्दन कुमार सिंह
Chandan Kumar Singh
S/O BRAHMADAYAL SINGH,
NEAR BAJRANG BALI TEMPLE, WARD-14,
VTC: Ramubariya,
PO: Majharia,
District: Buxar,
State: Bihar,
PIN Code: 802116,
Mobile: 9525252938

18011817



MC180118176FL



आपका आधार क्रमांक / Your Aadhaar No. :

6660 6269 6051

मेरा आधार, मेरी पहचान



भारत सरकार
Government of India



आधार

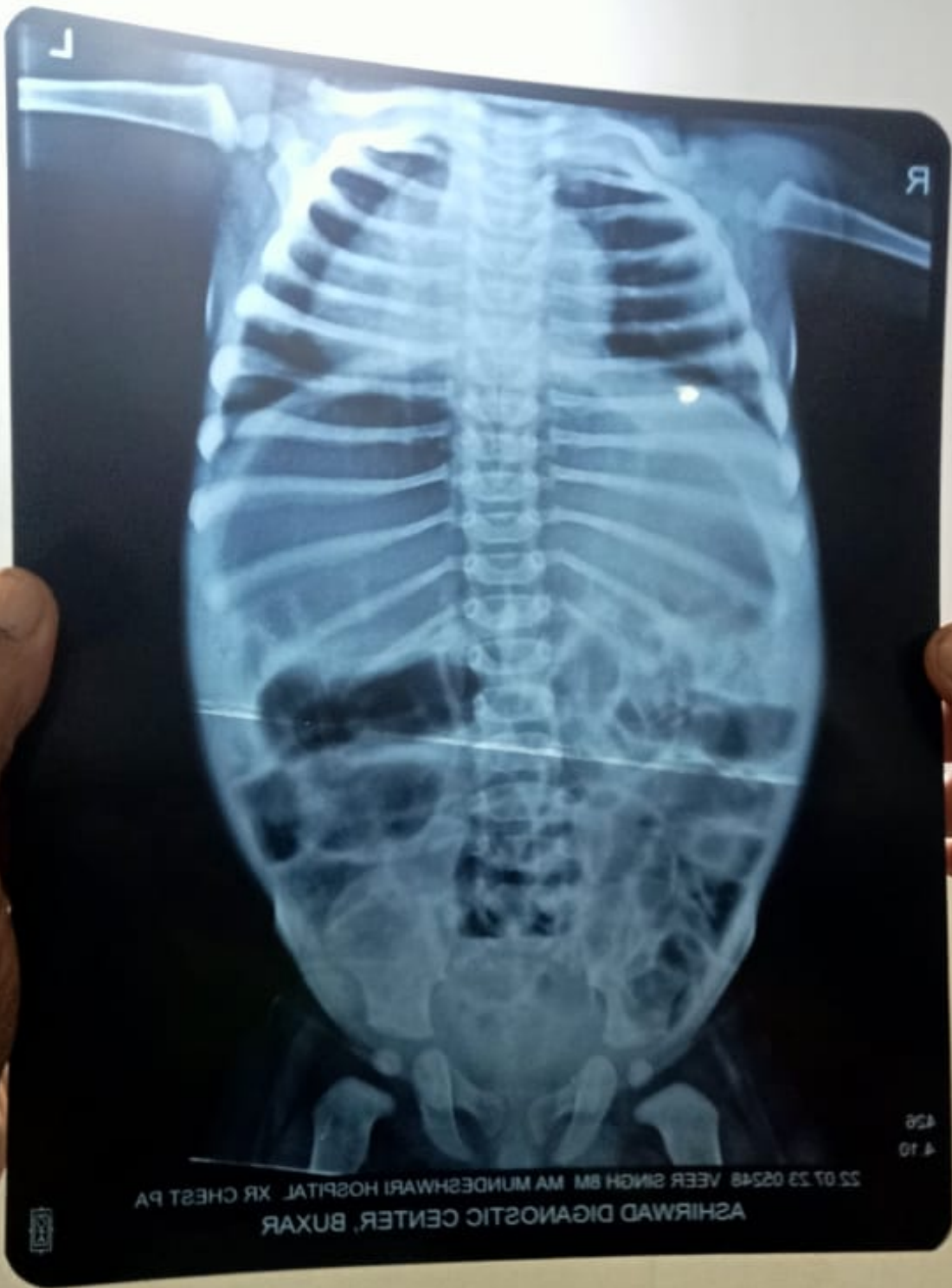Issue Date : 13/01/2012



चन्दन कुमार सिंह
Chandan Kumar Singh
जन्म तिथि / DOB : 15/06/1992
पुरुष / Male

6660 6269 6051

मेरा आधार, मेरी पहचान



ASHIRWAD DIAGNOSTIC CENTER, BUXAR
25 07 23 02548 VEER SINGH BM MA MUNDESHWARI HOSPITAL XR CHEST PA

4-10
426



Regd. No Bux-42/2022

CLASSIC PATHOLOGICAL LABORATORY

Singh Complex (Vishwakarma Engg. Infront of) Syndicate.
Golamber Road Buxar-802101

Mob.: 9472602503, 9060594898

CPL
Diagnostics

Dr. R. Raj
M.B.B.S



S.NO.06/23

Date:-20/07/23

Patient Name:- Veer Singh

Age:- 08 Mon Sex:-M

Referred by Dr : - Major P.K.Pandey M.B.B.S. M.D.

INVESTIGATION OF BLOOD

TEST	RESULT	NORMAL RANGE
C.R.P. Turbidimetric	8.7 mg/	0.0-6.0mg/L

Signature

- ❖ Not for medico legal purpose
- ❖ Lab 7:00 AM to 8:PM

 **CPL**
Diagnostics



Ashirwad DIAGNOSTIC CENTRE

Address - Adarsh Complex Bypass Road
Near Kali Mandir, Buxar (Bihar)
Email - ashirwaddiagnosticcentre@gmail.com
Mob. 9031698138, 9097066836, 9431098848

Patient ID : 22.07.23 05248
Patient Name : VEER SINGH 8M
Test Name : CHEST INCL.ABDOMEN AP VIEW
Referred By : MA MUNDRESHWARI HOSPITAL

Test Type : CR
Age/Gender : 000Y/M
Test Done On : 22-07-2023
Reported On : 22-07-2023

X-RAY CHEST AND ABDOMEN AP VIEW

The cardiac size and configuration are within normal limits.
The lung fields are clear. The broncho-vascular markings are normal.
The costo- and cardio-phrenic angles are free.
Both domes of the diaphragm are normal.
No abnormality is seen in the bones and soft tissues of the chest wall.
Distended air containing stomach.
Soft tissue outlines are normal.

IMPRESSION:

- **Distended air containing stomach.**
Suggested clinical correlation



Scan QR for Genuinity Check!

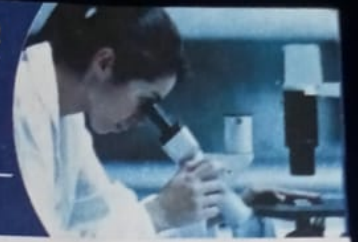
Dr. Vivek C.
Consultant Radiologist
MBBS, DMRD, DNB
Reg. No:- 63426 (KMC)

CLASSIC PATHOLOGICAL LABORATORY

Regd. No Bux-42/2022

Singh Complex (Vishwakarma Engg. Infront of) Syndicate.
Golamber Road Buxar-802101

Mob.: 9472602503, 9060594898



S.NO.10/23

Date:-16/07/23

Patient Name:- Veer Singh

Age: 08 Mons Sex:-M

Referred by Dr : - Major P.K.Pandey M.B.B.S. M.D.

INVESTIGATION OF BLOOD

TEST	RESULT	NORMAL. RANGE
ELECTROLYTE		
S.Sodium	138.7	136.0-149.0 mMol/l
S. Potassium	4.1	3.8-5.0 mMol/l
S.Chloride	102.0	100.0-109mMol/l

Signature

- ❖ Not for medico legal purpose
- ❖ Lab 7:00 AM to 8:PM

CPL
Diagnostics

1:30pm

Date... 16/12/23...

Maa Mundeshwari Children Hospital Buxar

Daily Progress and treatment chart

Name: Veer Singh Age: 8m Sex: M GA: from 800 to 800 WT:

VIII.

DOB	P	RR	BP	ORAL	TOB			DOA
					IV	URINE	STOOL	
ANTIBIOTICS								
800								
1000								
1200								
1400								
1600	91	174		99	X			
1800	97	178		97.4				
2000	90	165		91.4	X			
2200	90	167		101.4	X			
2400	91	156		100	X			
200	93	148		99.1	X			
400				100F	X			
600				99.5	X			
TOTAL								

145
117m 1480

8:30pm
2:20pm

3pm
3pm

4pm
4pm

4pm
4pm

4pm
4pm

4pm
4pm

4pm
4pm

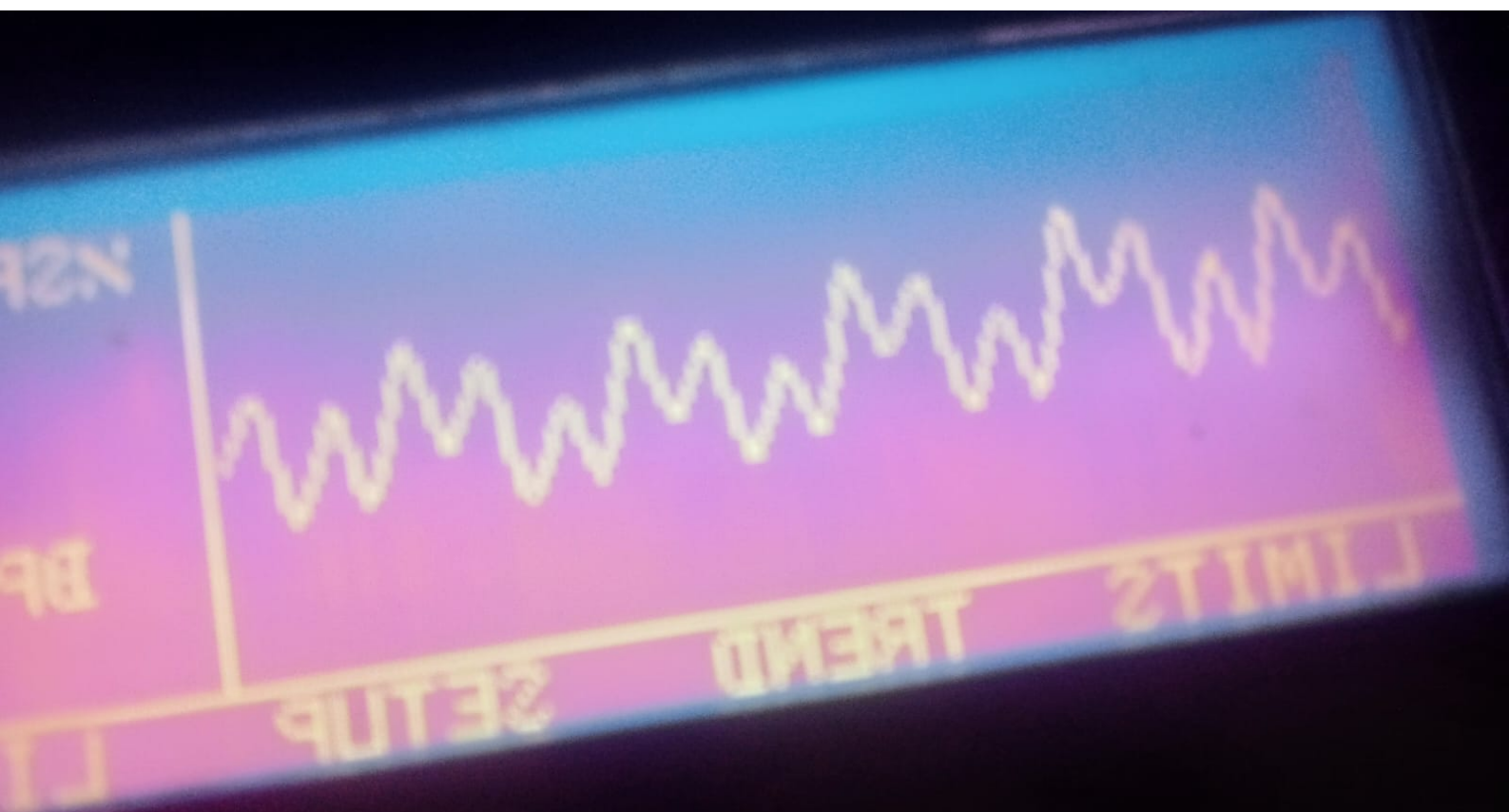
4pm
4pm


4pm
4pm

4pm
4pm

4pm
4pm

use use Echa chaw 7x Sawi Analgin Handkumari





S.NO.10/23

Date:-16/07/23

Patient Name:- Veer Singh

Age: 08 Mons Sex:-M

Referred by Dr : - Major P.K.Pandey M.B.B.S. M.D.

INVESTIGATION OF BLOOD

TEST	RESULT	NORMAL RANGE
TOTAL W.B.C COUNT	19,200/Cu mm	4000-10000/Cu mm
DIFFERENTIAL W.B.C. COUNT		
NEUTOPHILS	75%	50-70%
LYMPHOCYTES	20%	20-40%
EOSINOPHILS	05%	03-05%
MONOCYTES	00%	01-04%
BASOPHIL	00%	00-01%
HAEMOGLOBIN	8.4gm%	(11.0-14.6gm)
TOTAL R.B.C.COUNT	2.98	3.5-5.5 Million/cumm
HAEMATOCRIT (HCT/PCV)	25.2	37-54mg/d
MCV	61.0	80-100fl
M.C.H	18.6	27-34p
M.C.H.C.	30.1	31-37pg
PLALETES COUNT	3,06,000	150000-450000cu/mm

Signature

- ❖ Not for medico legal purpose
- ❖ Lab 7:00 AM to 8:PM

डा० (मेजर) प्रभात कुमार
Dr. (Major) Prabhat Kumar

MBBS, (Siliguri), MD(Ped), Delhi University
FNB (Ped Card), MCI recognised
Intervention Pediatric Cardiologist
(Expert in Pediatric, Fetal & CHD in Adult)



BCMR-41807

Mukunda Child Heart Clinic

बैक हवी रोड, (पोस्टल कोड सीटिंग) Rajendra Nagar, Patna-16
(दिनाकर गोलम्बर से 100 मीटर पुरुब, बैक जॉय इडिग के बडिग)

Mob. No:- 7979945262

Email:- kumarprabhat76@gmail.com

Patient's Name: MASTER VEER SINGH

Date: 10.08.2023

Ref. by Dr.: MAJOR P. K. PANDEY, MD

Age/Sex: 9 MONTHS/MALE

ECHOCARDIOGRAPHY REPORT

1. Situs solitus, Levocardia
2. AV-VA Concordant
3. SVC & IVC to dilated RA; All pulmonary veins to LA
4. IAS: 5 mm small sized OS ASD, Right to Left flow
5. IVS: INTACT
6. A-V Connection: Ebstein anomaly of TV, Moderate, low pressure TR, gdt= 16 mmHg;
Dilated TV annulus; Normal MV with no MR
7. Ventricles: Dilated ARV; Unipartite functional RV; Normal sized LV with normal
function (LVEF-56%)
8. V-A Connection: Normal; No AS/AR/PS; Mild PR; Confluent & fair sized branch PAs
9. Aortic arch: Left arch with normal branching pattern; No CoA/PDA
10. Others: No PAH; No PE/Vegetation; Coronaries: Normal

Conclusion: CYANOTIC CHD
Ebstein anomaly of TV (Moderate, Type B, Grade-3)
Small sized OS ASD
Moderate low-pressure TR
Dilated RA & ARV; Hypoplastic functional RV
Fair LV function

Dr (Maj) Prabhat Kumar
Senior Consultant Pediatric Cardiologist

Thanks for referral

ADU

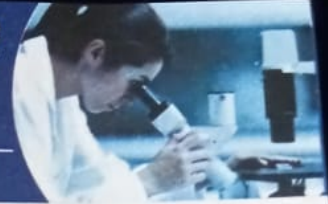Surgical correction

CLASSIC PATHOLOGICAL LABORATORY

Regd. No Bux-42/2022

Singh Complex (Vishwakarma Engg. Infront of) Syndicate.
Golamber Road Buxar-802101

Mob.: 9472602503, 9060594898



S.NO.10/23

Date:-16/07/23

Patient Name:- Veer Singh

Age: 08 Mons Sex:-M

Referred by Dr : - Major P.K.Pandey M.B.B.S. M.D.


INVESTIGATION OF BLOOD

TEST	Result					Normal. Range
WIDAL TEST (Slide method)						
Antigen	Agglutinin Titre					
	1:20	1:40	1:80	1:160	1:320	
S.TYPHI 'O'	+	+	+	+	-	
S.TYPHI 'H'	+	+	+	-	-	
S.PARATYPHI 'AH'	+	+	-	-	-	
S.PARATYPHI 'BH'	+	+	-	-	-	
R/A For Malaria	NEGATIVE					NEGATIVE

Signature

Lab hour 7:00 A M.to 8: P.M

Not for medico legal purpose



डा.0 (मेजर) प्रभात कुमार
Dr. (Major) Prabhat Kumar

MBBS, (Siliguri), MD(Ped), Delhi University
 FNB (Ped Card), MCI recognised
 Intervention Pediatric Cardiologist
 (Expert in Pediatric, Fetal & CHD in Adult)



Mukunda Child Heart Clinic

ब्लॉक नं. 01, (पेठगाँव का सीटिंग) Rajendra Nagar, Patna-16
 (विमान अड्डे से 100 मीटर पूर्व, बैंक ऑफ़ इंडिया के सामने)
 Mob. No:- 7979945262
 Email:- kumarprabhat76@gmail.com

Master Veer Singh
 9 M / 8 kg
 Dated: 10/8/23

Thanks for referral
 Dr. Manoj P. K. Pandey,
 MD



Hb = 7.8 g/dl
 K/40 CHD
 for severe 2opiner
 of incidental murmur
 during LRTD

Echo

SIE: Cyanotic +
 SpO2 = 85-92%
 HR = 130/4
 CRT: Multiple clicks

Ebstein's Anomaly of RV
 Small ASD, RAL
 Dilated RA/RV
 Smallish FRV
 (Outlet/Impedimental)
 Moderate, low pressure
 TR

- 0 Cyanotic CHD
- 0 Ebstein's Anomaly
- 0 Anaemia

No AS/AS
 GUF

Adv
 0 Drop Furosemide 0.4ml x 2
 (80%)

0 Tab. Aldactone (25mg)
 1/4 ml x 2

③ Any iron to continue

श्री० (मैज०) प्रभात कुमार
Dr. (Major) Prabhat Kumar
MBBS (Surg), MD(Ped), Delhi University
FNB (Ped Card), MCI recognised
Intervention Pediatric Cardiologist
(Expert in Pediatric, Fetal & CHD in Adult)



Mukunda Child Heart Clinic
Bharathi Street, (behind) Rajendra Nagar Phase-16
(Sector number 16) Delhi 110029, New Delhi
Mob. No.: 7979945262
Email: kumarprabhat19@gmail.com

BCMR-41807

Patient's Name: MASTER VEER SINGH
Ref. by Dr.: MAJOR P. K. PANDEY, MD
Date: 10.08.2023
Age/Sex: 9 MONTHS/MALE

ECHOCARDIOGRAPHY REPORT

1. Sinus solitus, Levocardia
2. AV-VA Concordant
3. SVC & IVC to dilated RA: All pulmonary veins to LA
4. IAS: 5 mm small sized OS ASD, Right to Left flow
5. IVS: INTACT
6. A-V Connection: Ebstein anomaly of TV, Moderate, low pressure TR, gdt= 16 mmHg; Dilated TV annulus; Normal MV with no MR
7. Ventricles: Dilated ARV; Unipartite functional RV; Normal sized LV with normal function (LVEF-56%)
8. V-A Connection: Normal; No AS/AR/PS; Mild PR; Confluent & fair sized branch Pass
9. Aortic arch: Left arch with normal branching pattern; No CoA/PPDA
10. Others: No PAH; No PE/Vegetation; Coronaries: Normal

Conclusion: **CYANOTIC CHD**
Ebstein anomaly of TV (Moderate, Type B, Grade-3)
Small sized OS ASD
Moderate low-pressure TR
Dilated RA & ARV; Hypoplastic functional RV
Fair LV function

Dr. (Major) Prabhat Kumar
Senior Consultant Pediatric Cardiologist

Thanks for referral

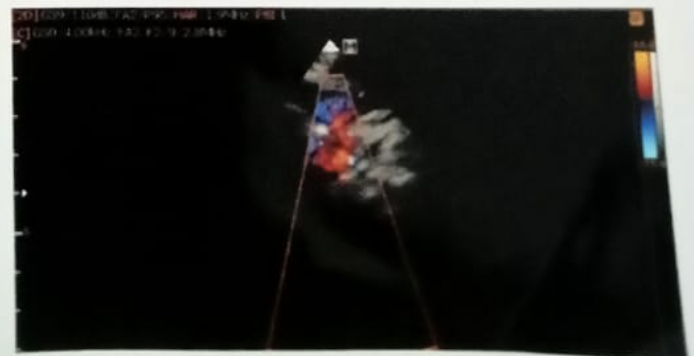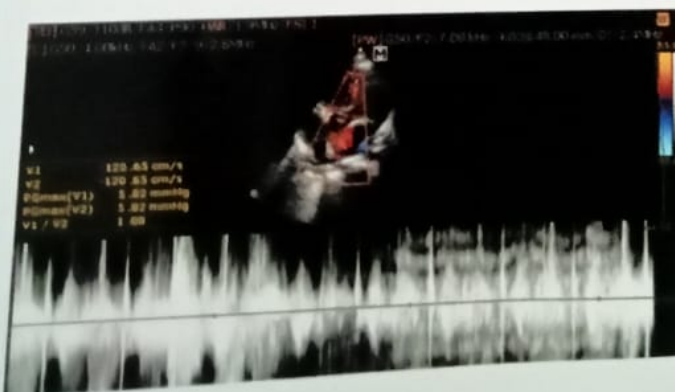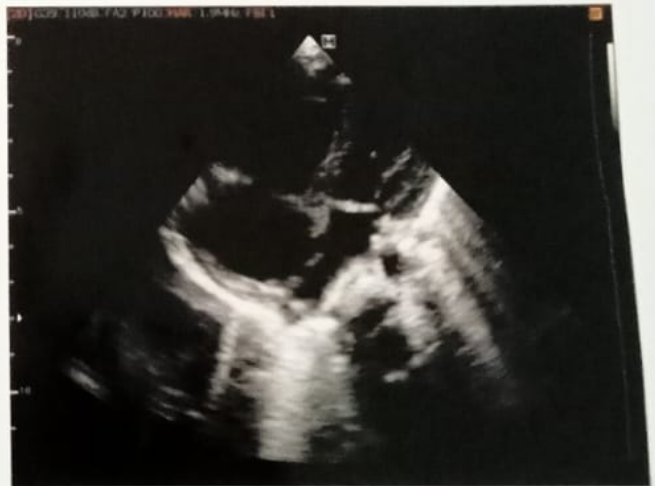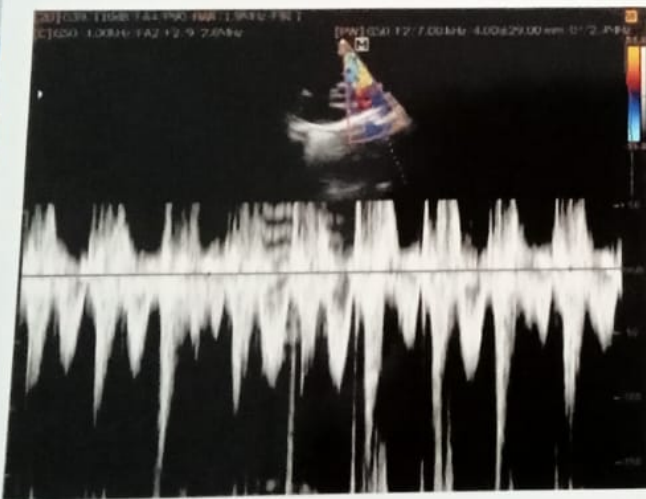
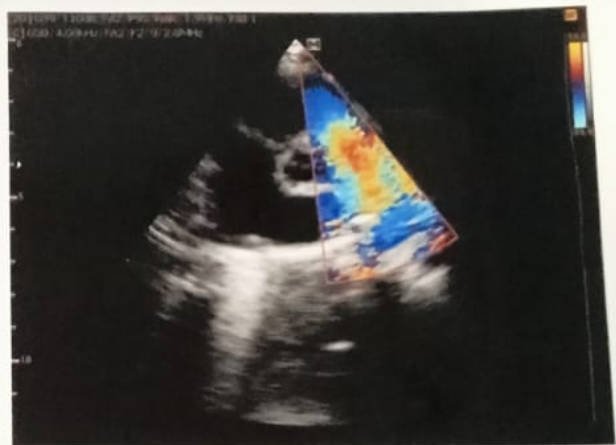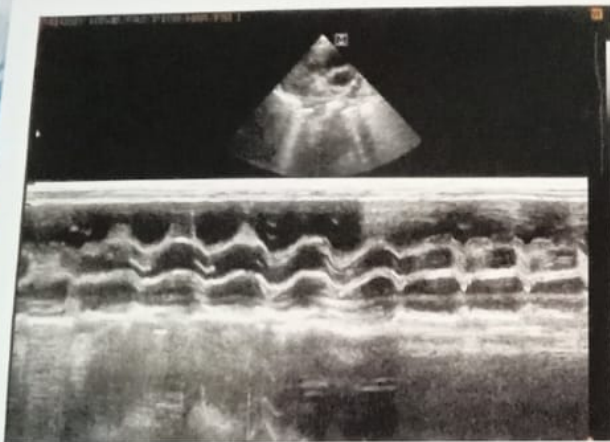
ABD
Surgical correction

④ Refu to High Cardiac Centre
for one & half ventrils
repair or simple TV valve
reconstruction

J. Prabhat

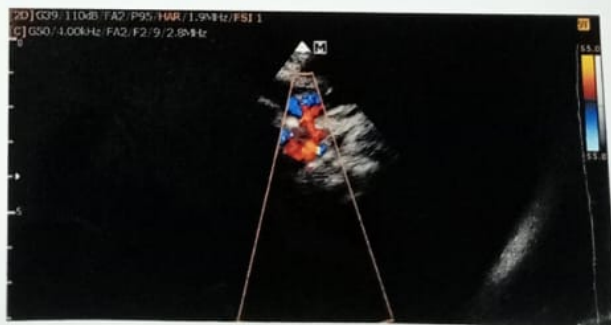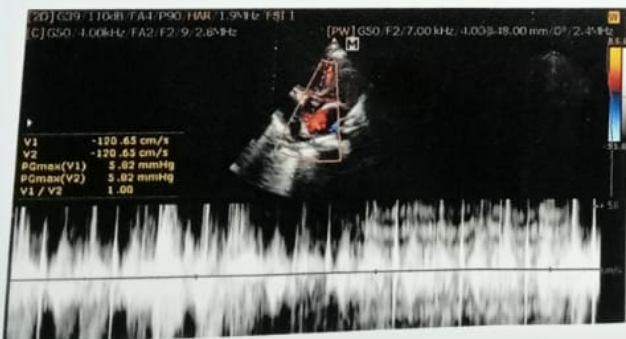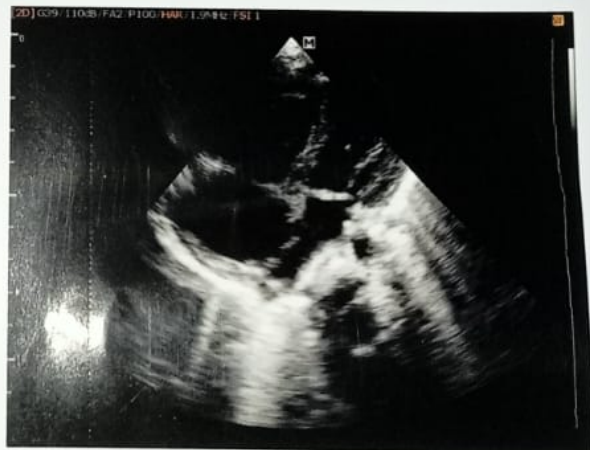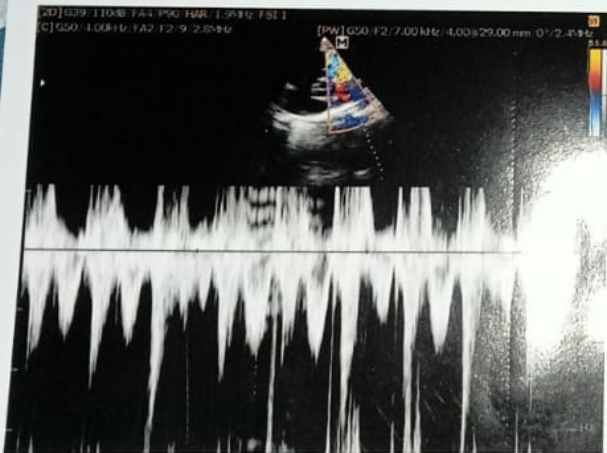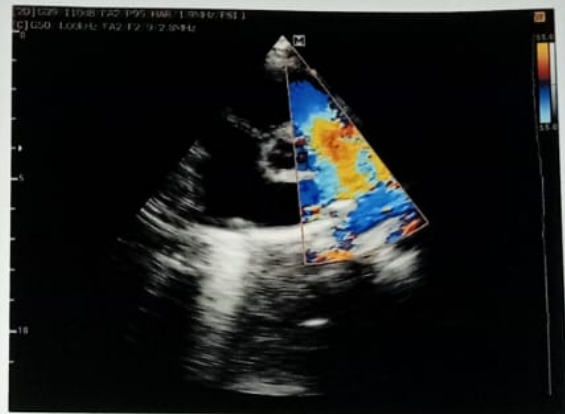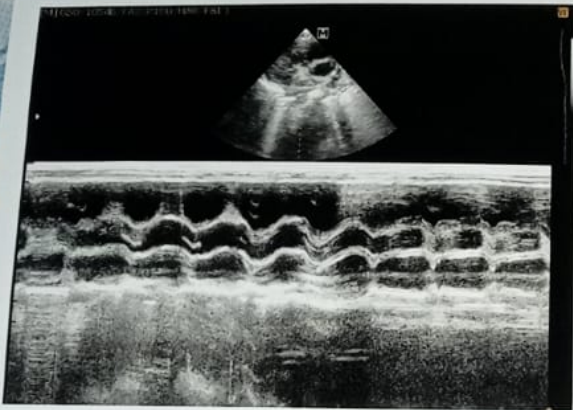
Sound Image Report

Patient		Exam	
ID	VEER SINGH	Accession #	23072023
Name		Exam Date	
Birth Date		Description	
Gender	Other	Sonographer	



Sound Image Report

Patient		Exam	
ID	VEER SINGH	Accession #	23072023
Name		Exam Date	
Birth Date		Description	
Gender	Other	Sonographer	



Patient ID : 05254
Patient Name : VEER SINGH
Test Name : CHEST INCL. ABDOMEN AP VIEW
Referred By : MA MUNDRESHWARI HOSPITAL

Test Type : CR
Age/Gender : 8/M
Test Done On : 23-07-2023
Reported On : 23-07-2023

FINDINGS:

CHEST PA VIEW

Bilateral lung fields are clear.
Bilateral CP angle are clear.
Cardiac size and configuration is normal.
Bilateral hilar and pulmonary vasculature appears normal.
Trachea and mediastinum is central.
Bones in view appears normal.


IMPRESSION :

No significant abnormality detected.

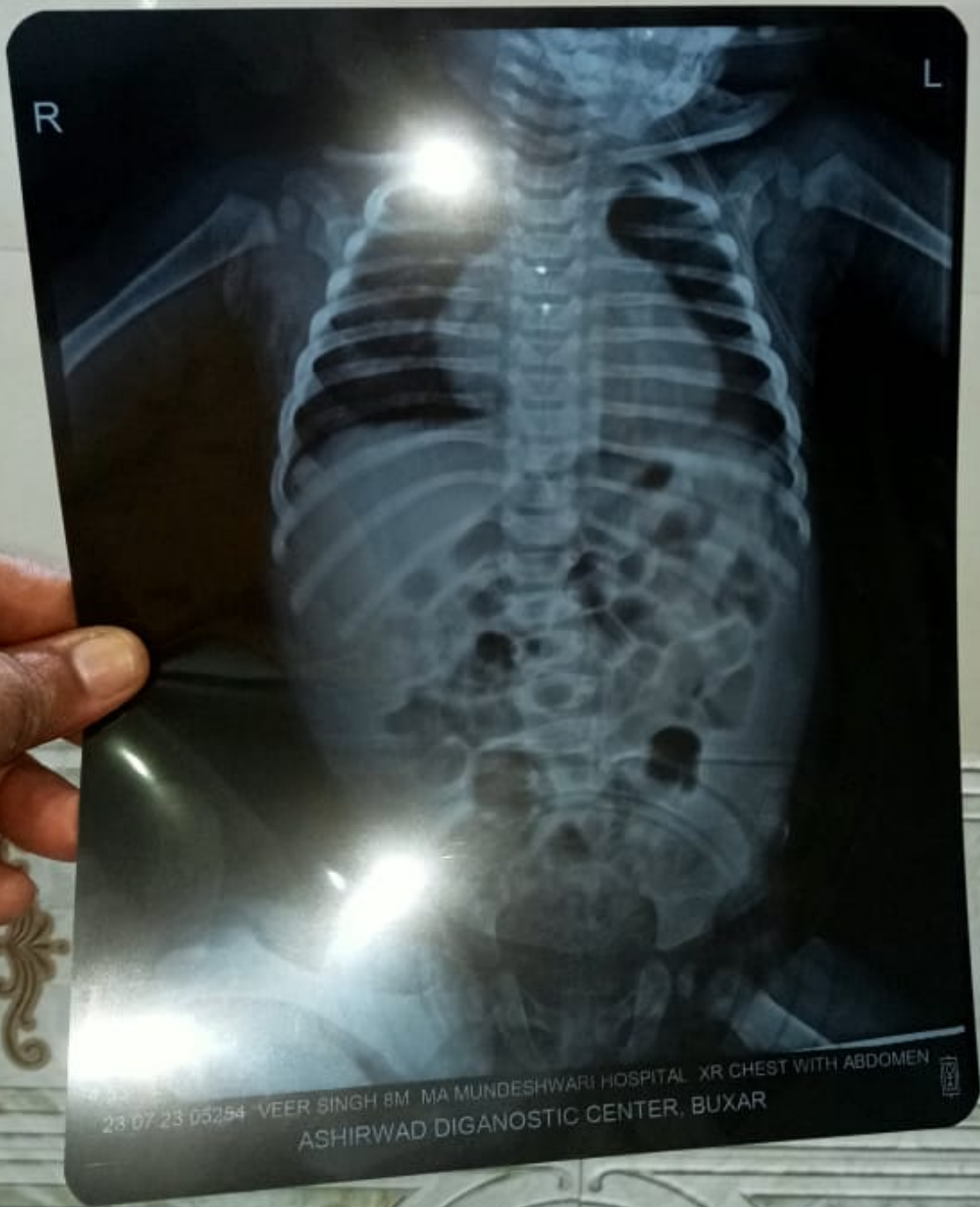X RAY ABDOMEN

FINDINGS:

Few air distended small bowel loops seen measuring upto 14mm, however No air fluid levels seen.
No free air under diaphragm
Visualised spine is normal.



Dr. M. Kaur
Consultant Radiologist
MBBS
MD (Radio Diagnosis)



23 07 23 05254 VEER SINGH BM MA MUNDRESHWARI HOSPITAL XR CHEST WITH ABDOMEN

ASHIRWAD DIGANOSTIC CENTER, BUXAR

Patient ID : 05254
Patient Name : VEER SINGH
Test Name : CHEST INCL. ABDOMEN AP VIEW
Referred By : MA MUNDESHWARI HOSPITAL

Test Type : CR
Age/Gender : 8/M
Test Done On : 23-07-2023
Reported On : 23-07-2023

CHEST PA VIEW

FINDINGS:

Bilateral lung fields are clear.
Bilateral CP angle are clear.
Cardiac size and configuration is normal.
Bilateral hilar and pulmonary vasculature appears normal.
Trachea and mediastinum is central.
Bones in view appears normal.


IMPRESSION:

No significant abnormality detected.

XRAY ABDOMEN

FINDINGS:

Few air distended small bowel loops seen measuring upto 14mm, however No air fluid levels seen.
No free air under diaphragm
Visualised spine is normal.


Dr. M. Kaur
Consultant Radiologist
MBBS
MD (Radio Diagnosis)

Patient ID : 05254
Patient Name : VEER SINGH
Test Name : CHEST INCL. ABDOMEN AP VIEW
Referred By : MA MUNDRESHWARI HOSPITAL

Test Type : CR
Age/Gender : 8/M
Test Done On : 23-07-2023
Reported On : 23-07-2023

FINDINGS:

CHEST PA VIEW

Bilateral lung fields are clear.
Bilateral CP angle are clear.
Cardiac size and configuration is normal.
Bilateral hilar and pulmonary vasculature appears normal.
Trachea and mediastinum is central.
Bones in view appears normal.


IMPRESSION :

No significant abnormality detected.

X RAY ABDOMEN

FINDINGS:

Few air distended small bowel loops seen measuring upto 14mm, however No air fluid levels seen.
No free air under diaphragm
Visualised spine is normal.



Dr. M. Kaur
Consultant Radiologist
MBBS
MD (Radio Diagnosis)